

TREATMENT OF PATIENTS WITH INTRA-ARTICULAR FRACTURES OF THE KNEE JOINT

Akhmedov Begzodbek Sherzodbek ugli

Andijan State Medical Institute

3rd year graduate student of the Department of

Traumatology and Orthopedics

Senior Lecturer: Mamazhonov K.X.

Abstract: In 2010–2022, the Center of Traumatology of the Republican Clinical Hospital of the Ministry of Health of the Republic of Uzbekistan, city of Andijan treated 145 patients with different types of intra-articular fractures of the knee joint. All patients underwent transosseous osteosynthesis (TOOS) with external fixation devices. They studied the results of treatment among 136 patients out of 145. The observation period was from 1 to 12 years. The results were evaluated on the basis of clinical X-ray examination data of patients.

Keywords: intra-articular fracture, knee joint, transverse osteosynthesis, restorative treatment, quality of life.

INTRODUCTION

The fractures of the knee joint area are one of the most severe limb bone injuries. The incidence of such fractures ranges from 4.0 to 6.1% of all lower extremity fractures and from 4.0 to 12.0% of all intra-articular fractures. Most authors note a significantly higher incidence of tibia proximal articular end fractures as compared with the fractures of the distal part of femur.

The treatment of such fractures is a difficult task. According to the data of different authors, the complications and unsatisfactory outcomes make up over 50.0%. The incidence of disability reaches 34.8% [2].

MAIN PART

The operation of TOOS was performed on the operating orthopedic table. Anesthesia is the central segmental blockade. When the analgesic effect was achieved, arthroscopy was performed with washing and knee joint revision. Further, the traction along the axis of the lower limb was carried out on the orthopedic table with the aim of repositioning and elimination of fragment gross dislocations, which was controlled by knee radiography in standard projections. At that, when the reposition was achieved with the restoration of articular surface congruence, a closed TOOS was used with an external fixation device. If the closed reposition was unsuccessful (in 36 cases of tibial condyle fractures), open surgical intervention was used to ensure the elimination of all kinds of dislocations, and then the needles with stops were

introduced through the condyles of the femoral and tibia bones, and Shantz screw-rods were inserted which provided the coaptation of fragments, as well as an optimal stability of fixation. Similar Shantz screw-rods were inserted in the main fragments of the femur or tibia, which were fixed on the support of the external fixation apparatus. The supports were joined together by threaded rods [3].

During the fractures of femur condyles after the preliminary reposition of the femur fracture, Schantz screw-rods were introduced at the level of the upper and the lower third of the diaphysis (or a combination of spokes and screws) and were fixed in two circular or arcuate supports of the device. Similar Schantz screws were inserted in the proximal metaphysis, or in the upper third of the tibial bone diaphysis, or a combination of spokes and screws was also used, which were fixed in the distal support of the external fixation device. All supports were joined in pairs by threaded rods. A screw-rod of Schantz was inserted in the damaged condyle of the femur, and it was fixed to the bracket in support of the mobile reposition node, which was mounted on the intermediate support of the device. The displacement of the Schantz screw in support of the mobile reposition node provided the final repositioning of the condyle fracture and the coaptation along the fracture plane. On reaching the reposition through the condyles of the femur, a spoke with an abutment was introduced and fixed to the device support along the side of the damaged fragment. The introduction of this spoke provided the reliability and the stability of fixation increased [Figure 1]. 1 month after the operation, the support installed in the proximal end of the tibia was dismantled, the screws-rods and spokes were removed, which provided the possibility of early active movement initiation in the knee joint.

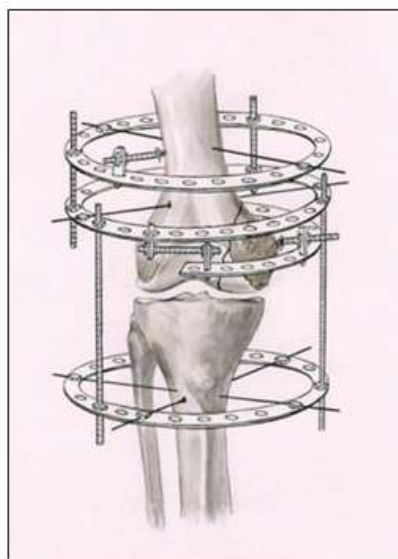


Figure 1: The scheme of transosseous osteosynthesis and the layout of the external fixation device at femoral condyle fractures [5]

CONCLUSION

They performed the analysis of the treatment of 136 patients with the fractures

of the knee joint area, among them were 24 patients with intra-articular fractures of the femoral condyles and 112 patients with the fractures of the tibial condyles. The observation period made 1–12 years from the moment of the operation.

We used a comprehensive clinical and radiological assessment of treatment outcomes, as well as the assessment of life quality conditioned by health.

The analysis of patient treatment results with intra-articular fractures of the knee joint area showed that the outcomes depend on the damage type and severity, the quality and the accuracy of repositioning with the restoration of congruence in the knee joint. The greatest number of satisfactory, as well as unsatisfactory results, was obtained with polyfragmentary and impression - compression fractures of the tibial condyles, which was determined by the severity of the lesions with massive destruction of bone articular surfaces that make up the knee joint.

REFERENCES:

1. Litvina EA. Operative treatment of distal femur fractures among the patients with combined and multiple trauma. In: Litvina EA, Skoroglyadov AV, Yu SM, Radkevich SA, editors. Bulletin of Traumatology and Orthopedics. Brasil: Clinical Sports Medicine; 2015. p. 3-8.
2. Oganessian OV. Restoration of damaged joint components using articulated-distraction apparatus. In: Herald of Traumatology and Orthopaedics. Brasil: Clinical Sports Medicine; 2018. p. 68-70.
3. Zwipp H, Tscherne H, Wülker N, Grote R. Intra-articular fracture of the calcaneus. Classification, assessment and surgical procedures. *Unfallchirurg* 2019;92:117-29.
4. Рахматов, З. Н., & Рашидов, Д. Н. (2023). ПУТИ СОВЕРШЕНСТВОВАНИЯ МЕХАНИЗМА РАЗРАБОТКИ МАРКЕТИНГОВОЙ СТРАТЕГИИ АО «ЎЗТЕМИРЎЛЎЛОВЧИ». *INNOVATIVE ACHIEVEMENTS IN SCIENCE* 2022, 2(17), 55-60.
5. Vityugov IA. Operative treatment of posttraumatic deforming arthrosis of the knee joint. In: Vityugov IA, Stepanov VS, editors. Orthopaedic Traumatol. Brasil: Clinical Sports Medicine; 2019. p. 7-12.